

Surgical Treatment for Postherniorrhaphy Neuropathic Inguinodynia: Triple Neurectomy with Proximal End Implantation

PARVIZ K. AMID, MD

summary The recommended surgical treatment for chronic neuropathic pain after herniorrhaphy has been a 2-stage operation that includes ilioinguinal and iliohypogastric neurectomies through an inguinal approach and genital nerve neurectomy through a flank approach. Equally effective is a 1-stage procedure involving the resection of all 3 nerves from an anterior approach. Simultaneous resection of the ilioinguinal, iliohypogastric, and genital nerves is performed with implantation of their proximal ends and without mobilization of the spermatic cord. □

Although inguinodynia is a potentially disabling condition, it remains an underrated complication of inguinal hernia repair. Surgeons are able to pay more attention to addressing pain because of the reduced recurrence rate caused by advances in hernia surgery.

The pain complex syndrome of postherniorrhaphy neuropathic inguinodynia includes pain (neuralgia), burning sensation (paresthesia), hypoesthesia, and hyperesthesia, with radiation of the pain to the skin of the corresponding hemiscrotum, labium majus, and Scarpa's triangle. Symptoms are frequently triggered or aggravated by walking, stooping, or hyperextension of the hip and can be decreased by recumbency and flexion of the thigh. These aspects of the pain syndrome suggest that traction of the involved nerve plays a major role in the postherniorrhaphy pain syndrome, an issue that must be addressed in the surgical treatment of neuropathic inguinodynia.

The neuropathic pain complex can also be repro-

duced by tapping the skin medial to the anterosuperior spine of the iliac bone or over an area of localized tenderness (Tinel's test). It is extremely difficult, if not impossible, to pinpoint the involved nerve for several reasons. First, peripheral communication between the ilioinguinal, iliohypogastric, and genital branch of the genital femoral nerve is very common and results in an overlap of their sensory innervation.^{1,2} Second, the innervation fields of the 3 nerves overlap.^{2,3} Third, at the spinal level, both ilioinguinal and iliohypogastric nerves derive from the 12th thoracic and first lumbar nerve and both the genital and ilioinguinal nerves receive communication from the first lumbar nerve.^{1,2} Fourth, more than 1 involved nerve can cause postherniorrhaphy pain syndrome (*Figure 1*).

Peripheral nerve block or differential paravertebral root block, although helpful for differentiating neuropathic from Non-neuropathic pain, is often inconclusive in the differential diagnosis of the involved nerve. Magnetic resonance neurography was helpful in few cases of this series.

ETIOLOGY AND PATHOLOGIC FINDINGS

The etiology of postherniorrhaphy inguinodynia includes Non-neuropathic causes such as periosteal reaction (due to suture or staple into the pubic tubercle), scar tissue formation, and mechanical pres-

From the Lichtenstein Hernia Institute and the Departments of Surgery, Harbor-UCLA and Cedars-Sinai Medical Centers, Los Angeles, Calif.

Correspondence: Parviz K. Amid, MD; Lichtenstein Hernia Institute, 5901 W. Olympic Blvd., Suite 207, Los Angeles, CA 90036; telephone (323) 938-5173; fax (323) 938-4863 (e-mail: pamid@onemain.com).

sure from rolled-up or wadded mesh and folded prosthetic material (to which I have referred elsewhere as “meshoma”)⁴ (Table). Neuropathic pain can be caused by compression of the nerve by perineural fibrosis (Figure 1), suture material (Figure 2), staples (Figure 3), prosthetic material (Figure 4), or actual nerve injury caused by partial or complete transection of nerves due to accidental cutting of the nerves, excessive traction of the nerves, or injury from electrocautery.

Actual nerve injuries can be caused by either lesional discontinuity (Figure 5) or complete transection injuries (Figure 6). Lesional discontinuity varies; it may consist of neurapraxia, in which the axons and myelin sheath are both intact; axonotmesis, interruption of the axons but with an intact myelin sheath; or neurotmesis, interruption of both axons and the myelin sheath (Figure 5).

Nerve injuries resulting in axonotmesis, neurotmesis, and complete transection of the nerve lead to traumatic neuroma formation via the inward migration and proliferation of fibroblast and perineural cells and the outward growth of axons. With complete transection, the neuroma manifests itself as a round tumor at the proximal cut end of the nerve (Figure 6). With lesional discontinuity, neuromas are manifested as small bulbar deformities along the course of the nerve (Figure 5).

SURGICAL TREATMENT

Pain related to neurapraxia, which may last for up to 6 months postoperatively, is usually self-limiting and does not require surgical intervention. Surgery is required, however, for perineural fibrosis; nerve entrapment by suture, staple, or prosthetic device; and neuroma formation as a result of axonotmesis, neurotmesis, or complete nerve transection.

Central and peripheral communication and frequent multiple nerve involvement (Figure 1) can make it extremely difficult, if not impossible, to discern which nerve is involved. Therefore, surgical treatment of postherniorrhaphy neuralgia should not be limited to a grossly involved nerve⁵ but should address all 3 nerves. Furthermore, the triggering or aggravation of the neuropathic pain complex by walking or hyperextension of the hip and its alleviation by recumbency and flexion of the thigh suggest that traction of the involved nerve, due to its adherence to the aponeurotic tissue of the groin, plays a major role in postherniorrhaphy pain syndrome.

TABLE SOURCES OF HERNIA PAIN

Non-neuropathic Pain

- Periosteal reaction
- Scar tissue
- Mechanical pressure of folded or wadded mesh (Figure 7)

Neuropathic Pain

- Nerve compression by:
 - Perineural fibrosis (Figure 1)
 - Suture (Figure 2)
 - Staples (Figure 3)
 - Mesh material (Figure 4)

Nerve injuries

- Neurapraxia
- Axonotmesis resulting in neuroma discontinuity (Figure 5)
- Neurotmesis resulting in neuroma discontinuity (Figure 5)
- Complete transection resulting in an end neuroma (Figure 6)

The surgical treatment of postherniorrhaphy neuralgia should include the insertion of the proximal cut ends under the internal oblique muscle fibers to avoid recurrent neuralgia triggered by adherence of the cut ends of the resected nerves to the aponeurotic elements of the groin. Surgical treatment for periosteal reaction or osteitis pubis consists of removing suture materials, staples, bulky suture knots, and bulk-forming or wadded mesh material from the inguinal region. Injection of 80 mg of methylprednisolone acetate under direct vision during the operative procedure may also be helpful.

Surgical treatment of neuropathic pain consists of resection of the involved nerves. Neurolysis is not recommended because it does not address neuromas or inevitable secondary scarification.⁵ Similarly, simple division of the nerves without complete resection is not recommended.

The recommended procedure is neurectomy. In this procedure, as suggested by Starling et al,^{3,5} the entire length of the nerves should be resected as proximally and distally as possible to include the involved segment and account for the numerous neural communications that inevitably exist among the 3 nerves. The transected nerve ends should be ligated to prevent neuroma formation. Any staple, suture, or prosthetic material along the course of the nerve should be

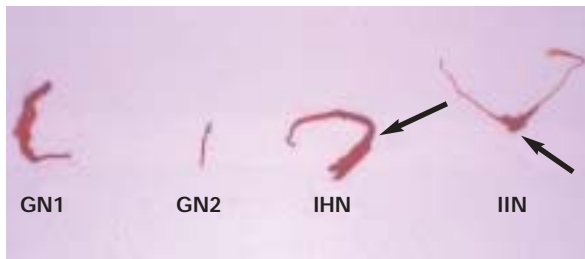


FIGURE 1. Perineural fibrosis involving ilioinguinal, iliohypogastric, and genital nerves. GN1 indicates genital nerve; GN2, tissue resembling genital nerve but histologically verified as fibroconnective tissue; IHN, iliohypogastric nerve; IIN, ilioinguinal nerve.




FIGURE 3. Nerve entrapment by staple (iliohypogastric nerve after laparoscopic repair).

included with the resected portion of the nerve.^{5,6} Complete removal of mesh is not necessary. We found, as other investigators had, that previous mesh repair did not predispose patients to neuropathic pain.^{5,6}

In addition, we suggest the following measures:

a. Resecting the genital nerve from the same anterior approach to avoid a second-stage operation through the flank and the possibility of an associated lumbar incisional hernia.⁶

b. Implanting the ligated proximal ends of the ilioinguinal and iliohypogastric nerves within the fibers of the internal oblique muscle and allowing the proximal cut end of the genital nerve to retract into the internal ring. This step prevents the cut ends of the nerves from adhering (via scarification) to the inguinal ligament and/or external oblique aponeurosis, which subjects the nerve to traction on walking or moving the hip joint and once again sets the stage for postoperative neuralgia.

c. Resecting and submitting any tissue fibers resembling a nerve as well as grossly evident nerve trunks for histologic verification to ensure that the resected specimens are neural tissue (Figure 1, GN2). With exploration and

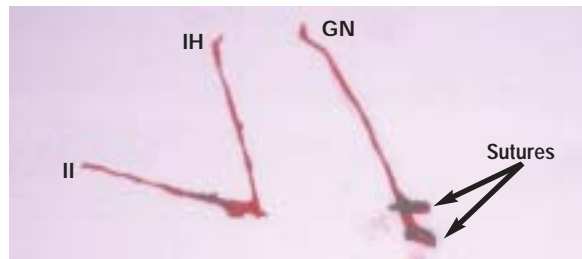


FIGURE 2. Nerve entrapment by sutures. II indicates ilioinguinal nerve; IH, iliohypogastric nerve; GN, genital nerve.



FIGURE 4. Nerve entrapment by a mesh plug.

experience, intraoperative frozen section may not be necessary, although it can be helpful.

STUDY POPULATION

Between 1995 and 2003, we operated on 131 patients. Fifty-nine had Non-neuropathic pain, distinguished preoperatively, localized groin firmness, and computed tomography scan finding (Figure 7); 72 patients had neuropathic pain. Three patients had bilateral neuropathic pain and had undergone 2 separate operations 3 months apart. All patients with neuropathic pain had previous herniorrhaphies and were referred after previous pain management treatment had failed. Fifty-six percent of patients with neuropathic pain had hernia repair without mesh; 46% had one or more previous mesh repairs, including a total of 4 laparoscopic hernia repairs.

We found, as had other authors,^{5,6} that previous mesh repair did not predispose patients to neuropathic pain. All patients with neuropathic pain, except 9 who had had previous multiple hernia repairs, had surgery under local anesthesia. None of the patients required mobilization of the spermatic cord. Eleven percent of the patients had histologically verifiable traumatic neuroma; 22% had nerve entrapment by suture (Figure 2), staple (Figure 3), or mesh plug

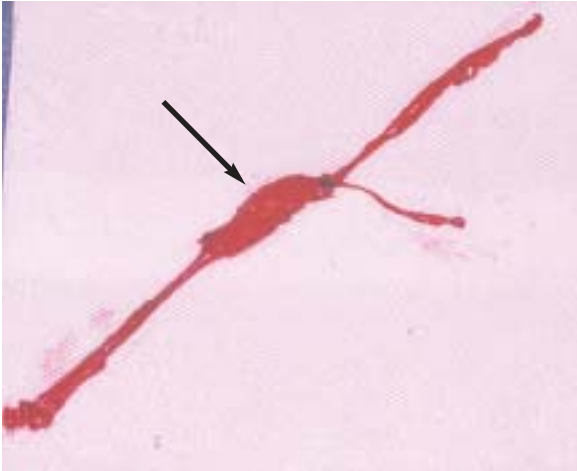

FIGURE 5. Neuroma formation as a lesion of discontinuity (arrow) of the genital nerve.

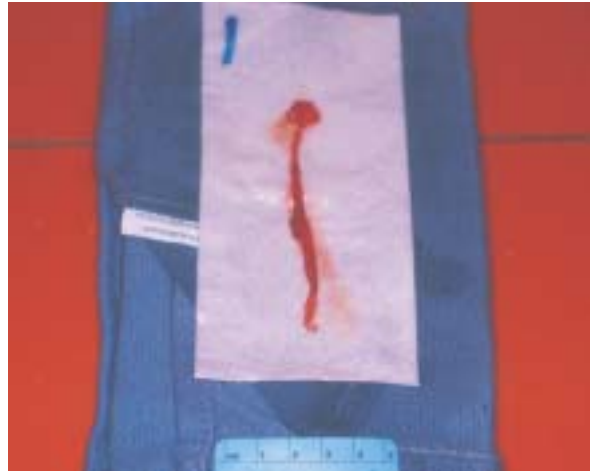

FIGURE 6. Neuroma formation at the cut end of a nerve.

(Figure 4); and 67% had perineural fibrosis (Figure 1).

The nerve affected most often by perineural fibrosis was the ilioinguinal nerve. The most frequent location of involvement was at the suture line of the external oblique closure, particularly at the level of the external ring. The second most commonly affected nerve was the iliohypogastric nerve.

Results

All patients were examined 3 days, 1 week, and 1 month postoperatively. Because patients with neuropathic pain have few or no objective signs, follow-up by physical examination beyond 1 month was deemed unnecessary. However, patients were contacted by telephone 6 months after the operation and instructed to report if pain had recurred. We received no calls from patients, their referring physicians, or their worker's compensation adjusters after the last examination. Sixty percent of patients made clear distinctions between incisional pain and preoperative neuropathic pain at the time of their first postoperative visit.

Eighty-two percent of patients reported complete elimination of pain within a month after surgery. Sixteen percent of patients had transient incisional pain for a few months that they characterized as distinctly different from their preoperative pain, with no functional impairment. Four patients (3%), all of whom had worker's compensation cases in litigation, reported that their pain had not improved. All but 4 patients with worker's compensation cases were able to return to work without restrictions. Many patients in this group felt vindicated in their complaints when it

became evident that they were not "crazy" or "malingering." All other patients reported a satisfactory quality of life after their operations. Even those with transient mild pain graded their pain as insignificant and clearly different from their preoperative pain.

Reported results of the 2-stage operation (89% success rate after the first stage and unspecified increased success rate after the second stage³) are comparable to those from our 1-stage triple neurectomy, with a 98% success rate. The important difference is that the 1-stage procedure obviates a second operation and the possibility of an associated lumbar incisional hernia.

DISCUSSION

Inguinal hernia repair can result in significant complications. Among these is postherniorrhaphy neuralgia, a potentially disabling condition. It is important to determine whether the patient had groin pain prior to hernia repair and whether the preoperative pain was the same in character as the postoperative pain. In addition, it is appropriate to determine how long after hernia repair the patient's inguinodynia began and whether the patient can differentiate the postoperative surgical pain from the pain of inguinodynia. Patients should be informed of the remote possibility of central and deafferentation pain.

In order not to raise a red flag, we avoid such terms as "nerve entrapment" for compression of the nerve(s) caused by "perineural fibrosis," a naturally occurring condition after inguinal hernia repair. Similarly, it is important not to use the term "mesh inguinodynia," which implies chronic pain caused by

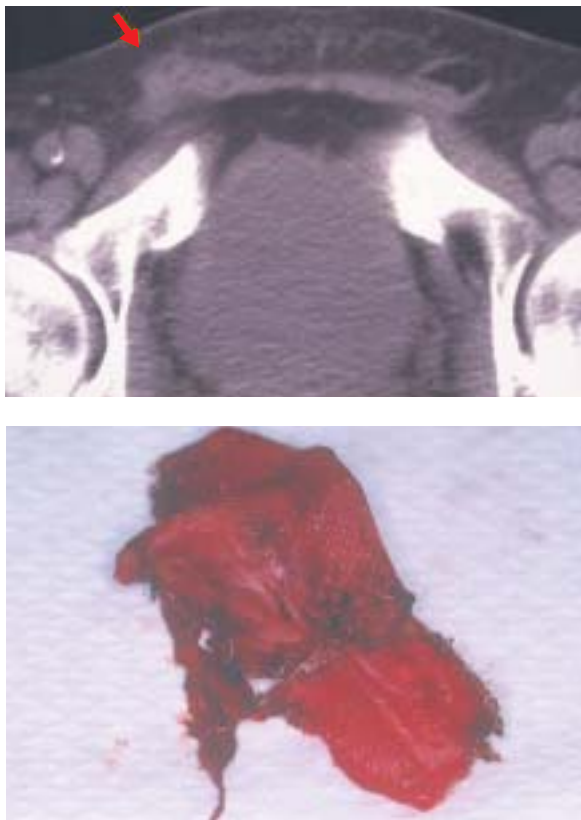


FIGURE 7. Computed tomography scan image (top) of a “meshoma” (arrow) and its corresponding explanted specimen (bottom), a Magnetic Resonance Angiogram/3D reconstruction.

the mesh itself. In a published series of 234 patients with postherniorrhaphy neuralgia in which the term “mesh inguinodynia” was used,⁷ only one-third of the patients had had previous mesh repair; the remainder had undergone repair with no mesh. This confusion in terms suggests that the term “mesh inguinodynia” was not supported by the data presented.

In another series of 315 patients with postherniorrhaphy chronic pain, none of the patients had had a previous mesh repair.⁸ Furthermore, 3 European studies^{9,10,11} all demonstrated that the use of mesh was not a factor in postherniorrhaphy chronic pain.

The most common cause of nerve injury is failure to identify and protect the nerves, particularly when dissection is minimized in order to complete the operation more rapidly. To reduce the incidence of this incapacitating complication of hernia surgery, the surgeon must have a thorough knowledge of the groin anatomy. To that end, we suggest the following:

- Avoid removal of the cremasteric layer to prevent injuring the ilioinguinal nerve.

- Avoid making the external ring too small to prevent tight contact between the ilioinguinal nerve and the suture line of the external oblique closure.
- Avoid lifting the ilioinguinal nerve from its bed on or within the cremasteric layer, particularly retracting the nerve behind the inguinal ligament, to prevent injury to the neurilemmal sheath of the nerve.
- Identify the nerves, and particularly avoid the so-called “minimal dissection” for completing the operation more rapidly.
- Avoid incising the subcutaneous adipose tissue hastily to prevent injury to the prematurely surfaced branches of the ilioinguinal or iliohypogastric nerves.
- Avoid deep staple or tack insertion during laparoscopic repair to prevent entrapment of the iliohypogastric, genital (medial to the internal ring), and ilioinguinal (lateral to the internal ring) nerves.

CONCLUSION

Simultaneous neurectomy of the ilioinguinal, iliohypogastric, and genital nerves for treatment of postherniorrhaphy inguinodynia obviates a second operation and is as effective as the 2-stage procedure.

References

1. Moosman DA, Oelrich TM. Prevention of accidental trauma to the ilioinguinal nerve during inguinal herniorrhaphy. *Am J Surg.* 1977;133:146-148.
2. Warwick R, Williams PL, eds. *Gray's Anatomy*. 35th ed. Philadelphia, Pa: WB Saunders; 1973:1050-1053.
3. Starling JR, Harms BA, Schroeder ME, Eichman PI. Diagnosis and treatment of genitofemoral and ilioinguinal entrapment neuralgia. *Surgery.* 1987;102:581-586.
4. Amid PK. The Lichtenstein repair in 2002: an overview of causes of recurrence after Lichtenstein tension-free hernioplasty. *Hernia.* 2003;7:101-115.
5. Starling JR, Harms BA. Ilioinguinal, iliohypogastric, and genitofemoral neuralgia. In: Bendavid R, ed. *Prostheses and Abdominal Wall Hernia*. Austin, Tex: RG Landes; 1994:351-356.
6. Amid PK. A 1-stage surgical treatment for postherniorrhaphy neuropathic pain: triple neurectomy and proximal end implantation without mobilization of the cord. *Arch Surg.* 2002;137:100-104.
7. Heise CP, Starling JR. Mesh inguinodynia: a new clinical syndrome after inguinal herniorrhaphy? *J Am Coll Surg.* 1998;187:514-518.
8. Cunningham J, Temple WJ, Mitchell P, et al. Cooperative hernia study. Pain in the postrepair patient. *Ann Surg.* 1996;224:598-602.
9. The EU Hernia Trialists Collaboration. Repair of groin hernia with synthetic mesh: meta-analysis of randomized controlled trials. *Ann Surg.* 2002;235:322-332.
10. Bay-Nielsen M, Perkins FM, Kehlet H. Pain and functional impairment 1 year after inguinal herniorrhaphy: a nationwide questionnaire study. *Ann Surg.* 2001;233:1-7.
11. Vrijland WW, van Den Tol MP, Luijendijk RW, et al. Randomized clinical trial of non-mesh versus mesh repair of primary inguinal hernia. *Br J Surg.* 2002;89(3):293-297.

CS